



PATIENT

Gwen Horning

SPECIES

Canine

BREED

Shih Tzu

SEX

Female Spayed

AGE

10 years

WEIGHT

9.3lbs

INTERPRETED BY

Maggie Machen
 Lamy, DVM, DACVIM
 (Cardiology)

IMAGING PERFORMED BY

Sara Hansen

HOSPITAL NAME

Ark Animal Hospital

REFERRING VET

Dr. Jackson

INVOICE

32521

DATE

8/23/23

PRESENTING CLINICAL SIGNS

History: Grade 3/6 heart murmur.

ELECTROCARDIOGRAPHIC FINDINGS *Note: Single lead ECGs are evaluated as a rhythm strip. Morphology/MEA cannot be definitively commented on.

A single lead ECG is available; 50mm/s, 20mm/mV. The average heart rate is 1350bpm (range 110-150bpm). The rhythm is sinus in origin, with a p for every QRS complex and vice versa. The P and QRS morphologies are positive. No ectopic beats, pauses or other dysrhythmias observed. ECG diagnosis: Normal sinus rhythm with respiratory variation.

ECHOCARDIOGRAM FINDINGS

2D, m-mode, color flow and doppler imaging is available. Mild diffuse thickening of mitral valve leaflets with no prolapse into the left atrial lumen. Mild mitral regurgitation with no left atrial dilation. Normal LV diameter with adequate myocardial function. The tricuspid valve appears normal with no tricuspid regurgitation. Normal right atrial and ventricular diameter and morphology indicating no overt evidence of pulmonary arterial hypertension. The pulmonic and aortic valves are normal in morphology and mobility. Normal pulmonic and aortic outflow velocities with laminar flow. No obvious aortic or pulmonic insufficiency. No pericardial or pleural effusion noted. No obvious cardiac masses.

CARDIAC CHART

| CANINE CARDIAC PARAMETERS | MR VMAX (m/s) | TR VMAX (m/s) | LA/AO (Boon method) | LA/AO (Heart Base; Swe) | FS (%) | EF (%) | EPSS (cm) |
|---|---------------|---------------|---------------------|-------------------------|---------------------------------|--|--|
| NORMAL PARAMETER | 4.5-5.5 | <2.7 | 1.3 | <1.6 | 28-40 | 40-100 | <0.6 |
| PATIENT | NM | NA | 1.0 | 1.1 | 50 | 83 | 0.16 |
| CANINE CARDIAC PARAMETERS | HR (BPM) | AV VMAX (m/s) | PV MAX (m/s) | BODY WEIGHT (kg) | LA 2D short axis Base view (cm) | LVIDd Avg; 2D and m-mode short axis (cm) | LVIDs Avg; 2D and m-mode short axis (cm) |
| NORMAL PARAMETER | 50-100 | 0.7-1.7 | 0.7-1.6 | BELOW | BELOW | BELOW | BELOW |
| PATIENT | NM | 1.0 | 0.7 | 4.2 | 1.3 | 2.5 | 1.2 |
| *Normal chamber parameters expressed as a mean value (SD) | | | | 3 | 1.27 (5.3) | 2.46 (2.46) | 1.36 (5.5) |
| BODY WEIGHT DEPENDENT PARAMETERS | | | | 5 | 1.40 (4.5) | 2.74 (5.2) | 1.60 (4.7) |
| | | | | 10 | 1.50 (3.8) | 3.27 (3.5) | 2.06 (3.1) |
| Adapted from June Boon, Veterinary Echocardiography, 1998 | | | | 15 | 1.83 (2.0) | 3.71 (2.4) | 2.43 (2.1) |
| Rishniw M and Hollis NE, J Vet Intern Med 2000; 14:429-435 | | | | 20 | 2.02 (1.9) | 4.14 (2.2) | 2.80 (2.0) |
| Hansson et al, Vet Rad and Ultrasound 2002 | | | | 25 | 2.18 (2.4) | 4.48 (2.9) | 3.10 (2.5) |
| Bonagura et al. Echocardiography: principles of interpretation, Vet Clin North Am 15:1177, 1995 | | | | 30 | 2.33 (3.3) | 4.83 (3.9) | 3.39 (3.4) |
| | | | | 35 | 2.48 (4.3) | 5.17 (5.0) | 3.69 (4.5) |
| | | | | 40 | 2.62 (5.2) | 5.48 (6.1) | 3.96 (5.4) |
| | | | | 50 | 2.88 (7.1) | 6.07 (8.3) | 4.46 (7.4) |



PATIENT

Gwen Horning

SPECIES

Canine

BREED

Shih Tzu

SEX

Female Spayed

AGE

10 years

WEIGHT

9.3lbs

INTERPRETED BY

Maggie Machen
Lamy, DVM, DACVIM
(Cardiology)

**IMAGING
PERFORMED BY**

Sara Hansen

HOSPITAL NAME

Ark Animal Hospital

REFERRING VET

Dr. Jackson

INVOICE

32521

DATE

8/23/23

INTERPRETATION OF THE FINDINGS & FURTHER RECOMMENDATIONS

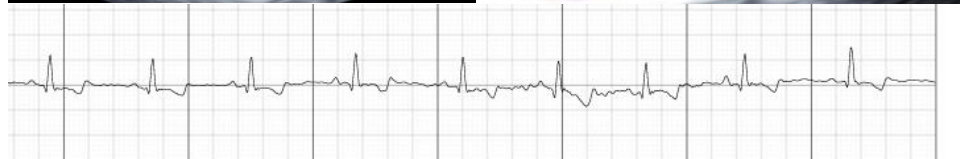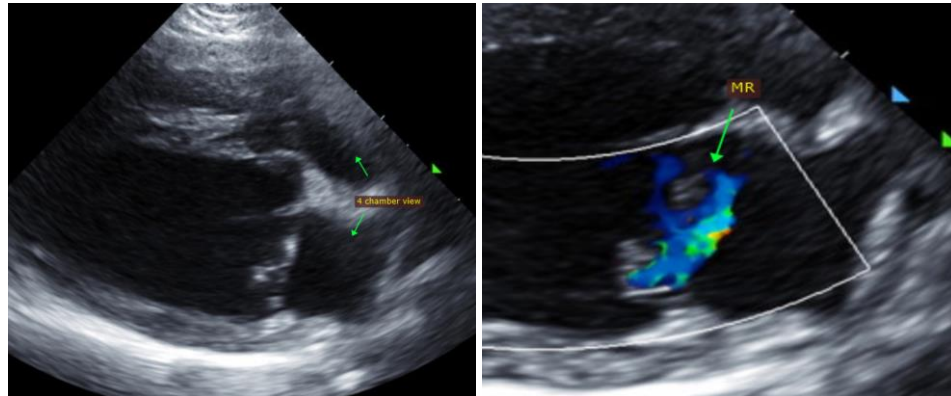
Chronic degenerative valve disease causing mild mitral regurgitation. Lack of significant left atrial enlargement indicates the current risk for complication is low. No concurrent issues such as pulmonary hypertension are noted in this study. The ECG is unremarkable with a normal sinus rhythm.

In an asymptomatic dog without significant left atrial enlargement, no cardiac medications are clearly indicated. Assessment of progression in the future will help predict long term prognosis, which is highly variable at this stage (B1). Omega fatty acid supplementation and mild salt restriction may be of some long-term benefit. Monitor for development of a cough, labored breathing, exercise intolerance or collapse episodes.

Anesthetic risk is considered mild if needed. Cardiac protective drug choices (opioid/benzodiazepine premedication, propofol or alfaxalone induction, isoflurane gas) are recommended. Pre-oxygenate for 5-10 minutes prior to induction. Monitor for arrhythmias, hypotension, and hypoxia both intra and post-operatively and intervene as necessary. Mild IV fluid restriction is recommended to avoid fluid overload. Avoid heart rate stimulating drugs such as atropine unless clinically indicated.

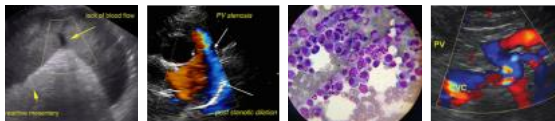
Recommend conservative monitoring with a recheck echocardiogram in 6-12 months, sooner if any development of clinical signs.

IMAGES



The information and recommendations provided are based on the images presented by the referring veterinarian. No evaluation can be communicated regarding pathology that was not visible in the image/video clips provided.

Thank you for this referral. This report was generated using transcription software, and minor dictation errors may be present. If the clinical or image interpretation does not parallel your findings or if I can be of any further assistance, please contact me.



PATIENT

Gwen Horning

Maggie Machen Lamy, DVM

Diplomate of the American College of Veterinary Internal Medicine (Cardiology)

info@sonopath.com

SPECIES

Canine

BREED

Shih Tzu

SEX

Female Spayed

AGE

10 years

WEIGHT

9.3lbs

INTERPRETED BY

Maggie Machen
Lamy, DVM, DACVIM
(Cardiology)

**IMAGING
PERFORMED BY**

Sara Hansen

HOSPITAL NAME

Ark Animal Hospital

REFERRING VET

Dr. Jackson

INVOICE

32521

DATE

8/23/23